

Mucinous Cystic Neoplasm of the Liver Mimicking as Hydatid Cyst: A Case Report

RANJITA PANIGRAHI¹, AJIT KUMAR SINGH², ARLENE BHUYAN³, AMARESH MISHRA⁴, SUBRAT KUMAR SAHU⁵

(CC) BY-NC-ND

ABSTRACT

Mucinous Cystic Neoplasms (MCNs) of the liver are rare cystic tumours, accounting for less than 5% of all liver cysts. They usually arise in the liver parenchyma and less frequently in the extrahepatic bile duct. Women in their 5th and 6th decades are predominantly affected. Various liver cystic lesions, such as hydatid cysts, simple cysts and endometriotic cysts, can mimic this rare entity radiologically. The present case involved a 38-year-old female who was admitted with chief complaints of skin rash, swelling in the face and feet, pain in all limbs, and abdominal distension for six months. She experienced significant weight loss and was unable to perform daily activities. Ultrasonography (USG) of the abdomen showed a well-defined multiloculated cyst in segment IV of the liver, which was further confirmed by a Contrast-enhanced Computed Tomography (CECT) scan. The patient underwent laparoscopic surgery based on the radiological diagnosis of a hydatid cyst. Histopathological (HP) study of the cyst wall revealed a diagnosis of MCN, which was further confirmed by Immunohistochemistry (IHC). The postoperative period remained uneventful. Complete surgical excision is the treatment of choice over conservative management and partial excision, as it has low recurrence rates and a good survival rate. Due to its rare presentation and the varied number of radiological differential diagnosis, it often leads to delayed or misdiagnosis. Authors hereby report the present case along with a brief review of the literature to increase radiological and clinical awareness, which is essential to keep MCN as a differential diagnosis during the initial evaluation of any cystic lesion of the liver.

Keywords: Abdominal distension, Calcification, Endometriotic cyst, Immunohistochemistry

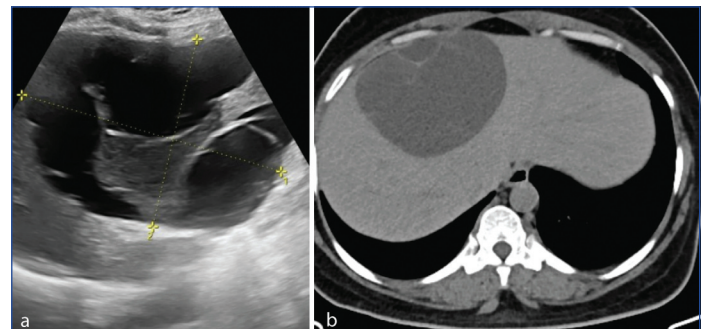
CASE REPORT

A 38-year-old female presented with a skin rash for six months, swelling on her face and feet for 4-5 months, pain in all limbs and generalised body aches for 3-4 months. She had difficulty getting up from a sitting (squatting) position for one month and experienced a low-grade fever in the last 20 days, along with abdominal distension. The low-grade fever was relieved with local medications. She experienced a weight loss of 2 kg over two months and was unable to perform daily activities. She was not a known case of diabetes, hypertension, or hypothyroidism.

On examination, her vital signs and chest X-ray were found to be within normal limits. During routine investigations, her Complete Blood Count (CBC), Renal Function Test (RFT), Thyroid Stimulating Hormone (TSH), urine examination and chest X-ray were normal. However, liver enzymes were elevated, with increased levels of serum lactate dehydrogenase at 860 U/L (reference limit up to 250 U/L), total creatine phosphokinase at 7840 U/L (reference limit <5 mg/L), and raised C-Reactive Protein (CRP) at 7.42 mg/L (reference limit <5 mg/L).

An Ultrasound (USG) of the abdomen and pelvis was performed due to abdominal distension. It showed the normal shape, size and echo pattern of all the abdominal and pelvic organs, except for a well-defined multiloculated cyst measuring 13.6×12.2×9.2 cm in segment IV of the liver [Table/Fig-1a]. A CECT scan of the abdomen [Table/Fig-1b] was conducted to confirm the USG findings, which revealed a multiloculated non enhancing cystic lesion of equivalent size, with thin hyperdense septa and foci of calcification in segment IV of the liver. Based on the radiological diagnosis of a hydatid cyst, the patient underwent laparoscopic surgery. The cyst wall was excised, the cavity was drained, and the specimen was sent for HP examination.

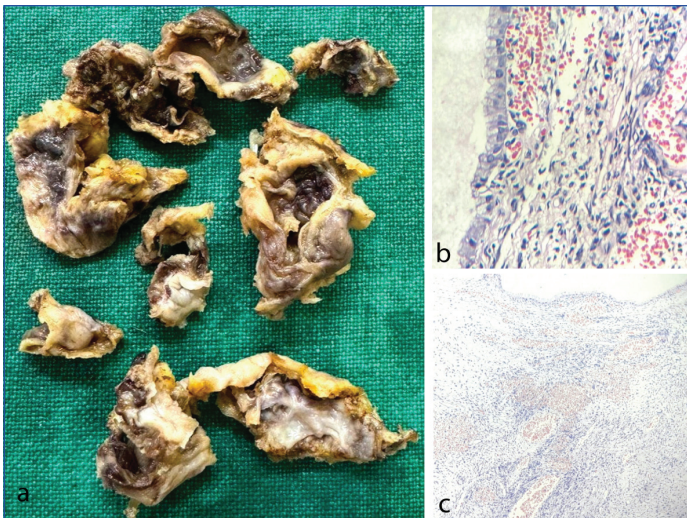
Gross examination revealed multiple irregular flap-like tissues of variable sizes, with the largest flap measuring 5.0×3.0×0.4 cm [Table/Fig-2a]. Multiple tissue sections studied microscopically



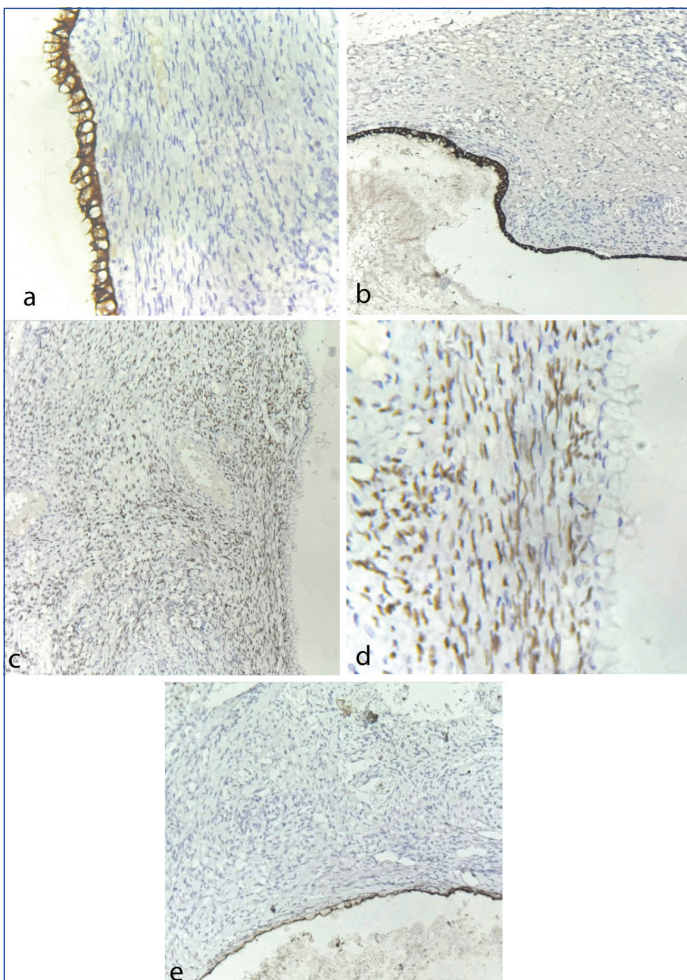
[Table/Fig-1]: Radiology images. a) USG of the abdomen showed a multiloculated cyst of size 13.6×12.2×9.2 cm in the segment IV of the liver. b) CECT of the abdomen showed a non enhancing cystic lesion measuring 13.6×12.2×9.2 cm in the segment IV of the liver.

revealed a cyst wall lined by a single layer of cuboidal to columnar mucinous epithelium with a basally placed nucleus and apical mucin [Table/Fig-2b]. The subepithelium showed ovarian-like stroma with spindle cells arranged in a storiform and short fascicular pattern, along with areas of haemorrhage and a significant number of variable-sized congested blood vessels [Table/Fig-2c]. No evidence of nuclear atypia, mitosis, dysplasia, or malignancy was observed. Additionally, no features of hydatid cysts were identified. An HP diagnosis of non invasive MCN of the liver was made, which was further confirmed by IHC. Epithelial markers such as Cytokeratin (CK) (CK7, CK19), and stromal markers such as Oestrogen Receptor (ER), Progesterone Receptor (PR) and Cluster Differentiation 10 (CD10) were used [Table/Fig-3-a-e]. The lining epithelial cells were positive for CK7 and CK19, while the ovarian-like stromal cells showed strong nuclear positivity for ER and PR, and were negative for CD10.

Patient's symptoms improved following the surgery, and she became ambulatory without support. The patient was discharged in stable condition. She remained asymptomatic and is doing well on follow-up after two years.



[Table/Fig-2]: Gross and histopathology images. a) Gross specimen showed multiple greyish white to greyish-brown irregular flap-like tissues ranging in size from 1.8×1.5×0.4 cm to the largest measuring 5.0×3.0×0.4 cm; b) Cyst wall lined by mucinous epithelium (H&E, 400x). c) Ovarian-like stroma and congested blood vessels below the epithelium (H&E, 200x).



[Table/Fig-3]: Immunohistochemistry images (IHC, 400x). a) CK7 showed positivity in lining epithelial cells of the cyst; b) CK19 showed positivity in lining epithelial cells of the cyst; c) ER showed strong nuclear positivity in stromal cells and negative in lining epithelial cells of the cyst; d) PR showed strong nuclear positivity in stromal cells and negative in lining epithelial cells of the cyst; e) CD10 showed negativity in stromal cells.

DISCUSSION

The MCNs of the liver pose a considerable diagnostic challenge, as they are rare tumours (accounting for less than 5% of all liver cysts) and can mimic various other liver cysts. The common differential diagnosis include hydatid cysts, simple cysts, Intrahepatic Papillary Neoplasm of the Bile Duct (IPNB), intrahepatic cholangiocarcinoma with cystic change and endometriotic cysts [1-4]. The female gender is predominantly affected, as noted in the literature review

[Table/Fig-4], which is similar to the findings in the present study [1-3,5,6]. Furthermore, women in their 5th and 6th decades are predominantly affected, as described by Quigley B et al., [7]. This contrasts with the present study, where the age of presentation is 38 years. However, the age of presentation of MCN in the current study is comparable to studies conducted by Sarangi S et al., and Tholomier C et al., [1,2].

Hydatid cysts are frequently associated with calcifications, but patients typically show positive serology. The cyst wall in the present case did not exhibit features of a hydatid cyst. Simple cysts can usually be distinguished by the absence of septations and papillary projections, along with the presence of serous cystic fluid. The presence of ovarian-like stroma is required to establish the diagnosis of MCNs of the Liver (MCN-L) and to differentiate it from IPNB [8]. The possibility of endometriosis was excluded as typical endometrial stroma was absent, and IHC was negative for CD10 in the stromal cells. Additionally, the epithelial cells were negative for ER and PR [4].

Previously, these MCNs were reported as 'biliary cystadenoma' and 'biliary cystadenocarcinoma'. Since the World Health Organisation (WHO) 2010 classification, they have been categorised into low, intermediate, high-grade and invasive carcinoma-related MCN-L. The WHO redefined and reclassified them as 'cyst-forming epithelial neoplasms' [5] and emphasised the requirement of ovarian-type stroma for the diagnosis of MCNs. Microscopically, the cyst is lined by a single layer of cuboidal to columnar epithelial cells with variable mucin. The subepithelium contains ovarian-type stroma. They are subdivided into two types: non invasive and invasive. Morphologically, invasive MCNs differ from non invasive MCNs by the presence of cellular pleomorphism, anaplasia and infiltration into the underlying fibrous stroma. The lining cells of the cyst exhibit considerable variation in size and atypia in their nuclei, as well as, loss of polarity. MCN-L remains the counterpart of MCN of the Pancreas (MCN-P). Both share similar findings in gross and microscopic examinations. Ovarian-like stroma remains a common clinicopathological feature in all [6].

As MCNs are slow-growing, they frequently reach a large size and can progress over the years to invasive carcinoma; hence, they are considered premalignant lesions [9]. However, their unknown oetiology, female predominance, age of onset and hormonally responsive ovarian-type stroma suggest ectopic organogenesis during embryologic development. It has been suggested that the proximity of the liver and gonads during embryonic development is responsible for the migration of gonadal cells to the liver surface, resulting in the ovarian stroma in these lesions [10].

Multiloculated cysts in the liver, initially diagnosed as hydatid cysts in radiology, have been described in almost all studies according to the literature review in [Table/Fig-4] [1-3,5,6]. It was only through histopathology that they were correctly diagnosed as MCNs with ovarian-like stroma, as was the case in the present study. Therefore, histopathology remains the gold standard for diagnosing MCNs of the liver. However, radiology is essential for initial investigation. Among the various radiological modalities, USG is the primary investigation modality of choice for patients presenting with complaints of abdominal distension, as it is a non invasive and cost-effective procedure. A CECT scan is often required for confirmation. Multiloculated cysts with septations and irregularly thickened walls are common radiological findings of MCNs in comparison to simple cysts [11].

CONCLUSION(S)

As MCNs are rare entities with unknown etiopathogenesis, non specific clinical presentations, a wide variety of radiological differential diagnosis, a high recurrence rate, and a premalignant nature, it is critically important to provide a precise pathological diagnosis for accurate treatment and follow-up. Complete

Authors and year of publication	Age	Sex	Chief complaint	Radiological findings and impression	Histological diagnosis	Outcome
Tekin E et al., 2024 [6]	47 50	F F	No active complaints Abdominal distension	Multiloculated cystic lesion-segment iii of liver: hydatid cyst cystic lesion-left lobe of liver: hydatid cyst	MCN-Low (L) grade MCN-low grade	No relapse No relapse
Anu D et al., 2024 [5]	52	F	Pain abdomen	Multiloculated septated cyst-central part of the liver: Hydatid cyst	MCN-L	Asymptomatic
Sarang S et al., 2022 [1]	32 57	F F	Pain abdomen Right upper abdomen pain	Multiloculated cyst-right lobe of liver: Hydatid cyst Largecystic lesion-segment IVB of liver: Hydatid cyst	MCN-L MCN-L	No recurrence Recurrence after 2 years
Soni S et al., 2021 [3]	55	F	Dull aching pain right hypochondrium	Cystic lesion-liver: Hydatid cyst	MCN-L non invasive	Free of symptoms
Tholomier C et al., 2019 [2]	37	F	Right upper quadrant pain	Multiloculated cyst- segment V/VIII of liver: Hydatid cyst	Biliary Mucinous Cystic Neoplasm (MCN)	No residual disease
Current case, 2024	38	F	Skin rash, swelling of face, feet and abdominal distension	Multiloculated cyst- segment IV of liver: Hydatid cyst	Mucinous Cystic Neoplasm (MCN)	Free of symptoms

[Table/Fig-4]: Review of literature [1-3,5,6].

surgical excision followed by HP study and IHC remains the gold standard for a definitive diagnosis. Low awareness due to the rarity of these tumours is thought to be the most significant cause of diagnostic and surgical errors. Increased radiological and clinical awareness is essential, and MCNs should be considered as a differential diagnosis during the initial work-up of any cystic lesion in the liver.

REFERENCES

- [1] Sarangi S, Nalwa A, Varshney VK, Yadav T, Vishwajeet V, Bharti JN. Mucinous cystic neoplasm of liver masquerading as Hydatid cyst: Important lesson learned. *Indian J Pathol Microbiol.* 2022;65(2):482-84. Doi: 10.4103/IJPM.IJPM_1106_20. PMID: 35435403.
- [2] Tholomier C, Wang Y, Aleynikova O, Vanounou T, Pelletier JS. Biliary mucinous cystic neoplasm mimicking a hydatid cyst: A case report and literature review. *BMC Gastroenterol.* 2019;19(1):103. Doi: 10.1186/s12876-019-1001-5. PMID: 31234803; PMCID: PMC6591873.
- [3] Soni S, Pareek P, Narayan S, Varshney V. Mucinous cystic neoplasm of the liver (MCN-L): A rare presentation and review of the literature. *Med Pharm Rep.* 2021;94(3):366-71. Doi: 10.15386/mpr-1543. Epub2021 Jul 29. PMID: 34430860; PMCID: PMC8357353.
- [4] Tsui WMS, Adsay NV, Crawford JM, Hruban R, Kloppel G, Wee A. Mucinous cystic neoplasms of the liver. In: Bosman FT, Carneiro F, Hruban RH, Theise ND (eds). *WHO Classification of Tumours of the Digestive System.* 4th ed. Lyon: International Agency for Research on Cancer 2010. pp. 236-38.
- [5] Anu D, Prasad T, Kumari M, Kant K. Mucinous cystic neoplasm of the liver: A rare case report. *Indian J Pathol Oncol.* 2024;11(2):179-82.
- [6] Tekin E, Taşkın T, Ayhan S. Mucinous cystic neoplasia mimicking hydatid cyst in the liver: Two rare cases. *Turk J Surg.* 2024;40(1):82-86.
- [7] Quigley B, Reid MD, Pehlivanoglu B, Squires MH, Maitheil S, Xue Y, et al. Hepatobiliary mucinous cystic neoplasms with ovarian type stroma (So-Called "Hepatobiliary Cystadenoma/Cystadenocarcinoma"): Clinicopathologic analysis of 36 cases illustrates rarity of carcinomatous change. *Am J Surg Pathol.* 2018;42(1):95-102. Doi: 10.1097/PAS.0000000000000963. PMID: 29016404.
- [8] Valasek M, Yeh M. Mucinous cystic neoplasm of the liver: Clinicopathologic features and differential diagnosis case review. *Pathology Case Reviews.* 2014;19(6):293-96.
- [9] Liu K, Zhang W, Liu S, Dong B, Liu Y. Hepatic endometriosis: A rare case and review of the literature. *Eur J Med Res.* 2015;20(1):48. Doi: 10.1186/s40001-015-0137-1. PMID: 25886632; PMCID: PMC4389341.
- [10] Hutchens JA, Lopez KJ, Ceppa EP. Mucinous cystic neoplasms of the liver: epidemiology, diagnosis, and management. *Hepat Med.* 2023;15:33-41. Published 2023 Mar 29. Doi:10.2147/HMER.S284842.
- [11] Mortelet KJ, Ros PR. Benign liver neoplasms. *Clin Liver Dis.* 2002;6(1):119-45.

PARTICULARS OF CONTRIBUTORS:

1. Professor, Department of Pathology, Kalinga Institute of Medical Sciences, Bhubaneswar, Odisha, India.
2. Assistant Professor, Department of Pathology, Kalinga Institute of Medical Sciences, Bhubaneswar, Odisha, India.
3. Postgraduate Student, Department of Pathology, Kalinga Institute of Medical Sciences, Bhubaneswar, Odisha, India.
4. Professor, Department of Surgery, Kalinga Institute of Medical Sciences, Bhubaneswar, Odisha, India.
5. Professor, Department of Surgery, Kalinga Institute of Medical Sciences, Bhubaneswar, Odisha, India.

NAME, ADDRESS, E-MAIL ID OF THE CORRESPONDING AUTHOR:

Ajit Kumar Singh,
House No-19, Sai Anandam Complex, Near Koel Campus, Patia-751024,
Bhubaneswar, Odisha, India.
E-mail: ajit.singh@kims.ac.in

PLAGIARISM CHECKING METHODS: [Jain H et al.]

- Plagiarism X-checker: Aug 05, 2024
- Manual Googling: Sep 28, 2024
- iThenticate Software: Nov 06, 2024 (15%)

ETYMOLOGY: Author Origin

EMENDATIONS: 6

AUTHOR DECLARATION:

- Financial or Other Competing Interests: None
- Was informed consent obtained from the subjects involved in the study? Yes
- For any images presented appropriate consent has been obtained from the subjects. No

Date of Submission: **Aug 03, 2024**

Date of Peer Review: **Sep 17, 2024**

Date of Acceptance: **Nov 08, 2024**

Date of Publishing: **Jan 01, 2025**